Maxillo-mandibular Relationship

- It is a registration of any positional relationship of the mandible to the maxillae.
- It is also known as: Maxillomandibular record or Maxillo-mandibular registration or Jaw relation.
- **Vertical Relation*:*** It is the separation between maxilla and mandible in a frontal plane.
- **Vertical Dimension*:*** It is the distance between two selected points, one on a fixed and one on a movable point.

  In general, the vertical measurement of the face could be recorded between any two arbitrary selected points which are usually located one above the mouth (like at the tip of nose) and other below the mouth (like at the tip of the chin in the midline region).

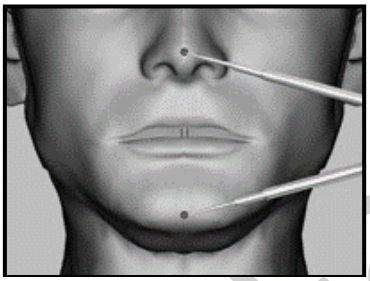

- **Physiological Rest Position:** It is the position of the mandible when an individual is resting comfortably in an upright position, the related muscles are in an equilibrium contractual activity and the condyles are in a neutral unstrained position.

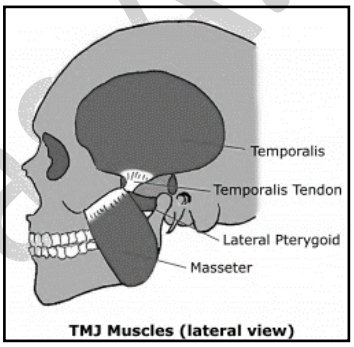

Physiological Rest Position (Minimal muscles contraction)

- **Rest Vertical Dimension:** It is the distance between two selected points (one at the tip of the nose and the other at the tip of chin (in the midline region) measured when the mandible is in the physiologic rest position.

- **Occlusal Vertical Dimension:** It is the distance measured between two points when the occluding members (teeth or occlusal rims) are in contact.

- **Inter-Occlusal Rest Space (Free-Way Space):** It is the distance between the occluding surface of maxillary and mandibular teeth when the mandible is in its physiological rest position. It is the difference between the vertical dimension of rest and the vertical dimension of occlusion.

RVD – OVD = Freeway space ⇨ normally ≈ (2mm)

RVD=Rest Vertical Dimension,
OVD=Occlusal Vertical Dimension
FWS= Freeway Space

Dr. Firas A. Farhan

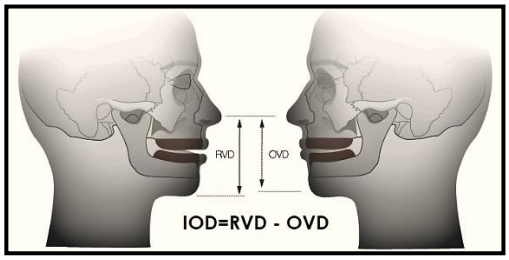

❖ Classification of Jaw Relations:

A- Orientation Jaw Relation: establish the references in the cranium use of a face bow device.

B- Vertical Jaw Relation: establish the amount of jaw separation that use for dentures

1. Vertical Jaw Relation at Rest Position (RVD)
2. Vertical Jaw Relation at Occlusion (OVD)

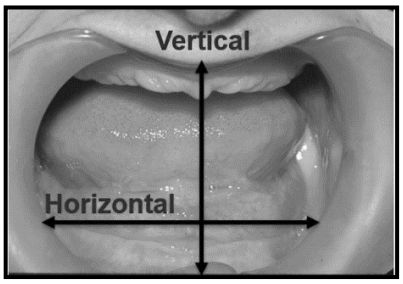

C- Horizontal Relation: establish front-to-back & side to side relations of one jaw to the other

1. Centric Jaw Relation
2. Eccentric Jaw Relation
   - *a- Lateral Jaw Relation*
   - *b- Protrusive Jaw Relation*

❖ Importance of vertical dimension:

A. Functional roles includes:

1. Mastication.
2. Deglutition (swallowing).
3. Phonetics.
4. Respiration.

B. Physiological roles: maintenance health of tissue (mucosa, bone, muscles and temporo-mandibular joint); also called Comfortable role.

C. Esthetic role

D. Psychological role (stress, nervous)

❖ Consequences of Increased Vertical Dimension:

1 Increased trauma to the denture bearing area (acceleration of residual ridge resorption).
2 Inharmonious facial proportion (increased lower facial height).
3 Difficulty in swallowing and speech
4 Pain and clicking in the temporo-mandibular joint and muscular fatigue.
5 Loss of biting power.
6 The sensation of a bulky denture.
7 Premature contact of upper and lower teeth.

Dr. Firas A. Farh

8 Instability of dentures due to their excessive height
9 Clicking of teeth in speech and mastication.
10 Excessive display of artificial teeth and gum.

Increased Vertical Dimension

❖ Consequences of Decreased Vertical Dimension:

1. Difficulty in swallowing and speech.
2. Pain and clicking in the temporo-mandibular joint and muscular fatigue.
3. Loss of muscle tone and presence of wrinkles and folds that is not due to age.
4. Decreased space of the oral cavity, and pushing the tongue backward.
5. Loss of biting power.
6. Naso-labial angle is less than 90°.
7. Angular chelitis due to the folding of the corner of the mouth.
8. Cheek biting.
9. Thinning of the vermilion borders of the lip
10. The prominence of lower jaw and chin

Decreased Vertical Dimension

Angular chelitis

❖ Methods of Recording Rest Vertical Dimension:

1. Facial measurements

The patient sit comfortably in upright position and his eyes looking straight at some object, which is on the same level. Insert the maxillary record base with the attached contoured occlusion rim. With an indelible marker, place a point of reference on the end of the patient's nose and another on the point of the chin. The patient asked to perform functional movements like wetting his lips, swallowing and to relax his shoulders (this is

Dr. Firas A. Farhan

done to relax the supra- and infra-hyoid muscles). When the mandible drops to the rest position, the distance between the points of reference is measured. Repeat this procedure until the measurements are consistent. Such measurements are helpful but cannot be considered as absolute.

2. Tactile sense

The patient sit upright and open his jaws wide until strain is felt in the muscles. When this opening becomes uncomfortable, ask them to close slowly until the jaws reach a comfortable, relaxed position. Measure the distance between the points of reference as made in facial measurements method.

3. Phonetics

Ask the patient to repeat pronounce the letter (**m**) a certain number of times, like repeat the name ***Emma*** until they are aware of the contacting of the lips as the first syllabus ***em*** is pronounced. When a patient has rehearsed this procedure, ask that they stop all jaw movement when the lips touch. At this time measure between the two points of reference.

4. Facial expression

The experienced dentist may notice the relaxed facial expression when the patient's jaws are at rest.

The following facial features indicate that the jaw is in its physiological rest position:

The upper and lower lips should be even antero-posteriorly and in slight contact in a single plane. The skin around the eyes and over the chin should be relaxed; it should not be stretched, shiny, or excessively wrinkled. Furthermore, the nostrils are relaxed and breathing should be unobstructed. These features are evidence of the rest position of the maxilla-mandibular musculature that used to record the rest vertical dimension.

5. Anatomical landmarks (Willis method)

The Willis guide designed to measure the distance from the pupils of the eyes to the corner of the mouth and the distance from the anterior nasal spine to the lower border of the mandible. When these measurements are equal, the jaws are considered at rest. The measurement accuracy is questionable in patients with facial asymmetry.

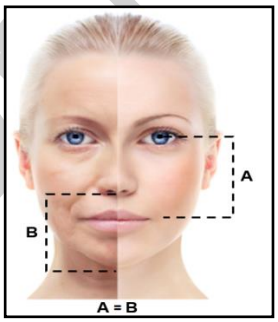

Willis Method

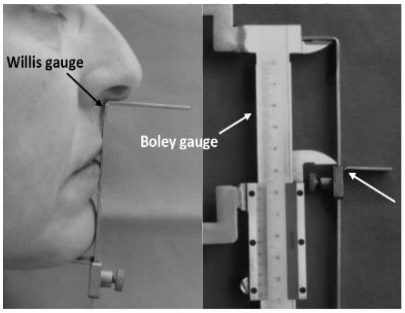

Willis method and Boley gauge used to measure the distance recorded by Willis

6. Electro-Myographic method (EMG)

By using a special device, which measures the tone of masticatory muscles, when the tone is at least value, which indicated that the muscles and the jaws are at rest position.

Dr. Firas A. Farhan

❖ Methods Of Recording Occlusal Vertical Dimension:

1. Pre-extraction records:

These records are made before the patient extracts all teeth and loses his occlusal vertical dimension; these records are:

A. Profile photographs

They are made and enlarged to life size. Measurements of anatomic landmarks on the photograph are compared with measurements using the same anatomic landmarks on the face. These measurements can be compared when the records are made and again when the artificial teeth are tried in. The photographs should be made with the teeth in maximum occlusion, as this position can be maintained accurately for photographic procedures.

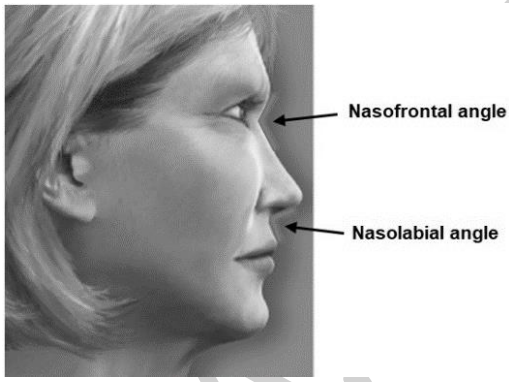

Profile photographs

B. Profile Silhouettes

An accurate reproduction of the profile silhouettes can be cut out in cardboard or contoured in wire. The silhouettes can be repositioned to the face after the vertical dimension has been established at the initial recording and/or when the artificial teeth are tried in.

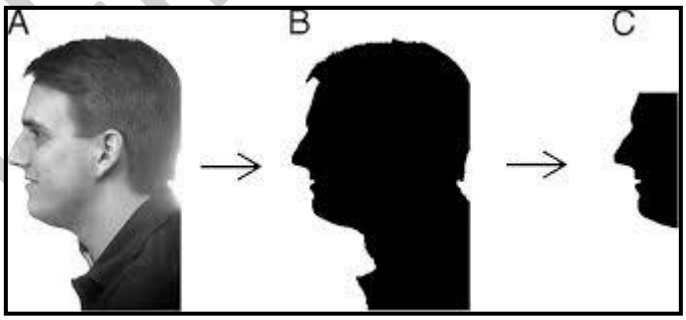

Profile Silhouette

C. Profile radiographs

It has been widely used by researches to measure the vertical dimension of occlusion rather than using in prosthodontic treatment for edentulous patients. The two types of radiographs are advocated; the cephalometric profile radiograph and radiograph of the condyles in the fossae. The disadvantages of this method are image distortion, radiation hazard and time consuming.

Dr. Firas A. Durhan

Cephalometric radiograph

D. Articulated casts

When the patient having a full dentition, an accurate cast has been made for the maxillary and mandibular arches. An occlusal record of the jaws in centric relation is used to mount the mandibular cast. After the teeth have been removed and edentulous casts have been mounted on the articulator, the inter-arch measurements are compared. Generally, the edentulous ridges will be parallel one to another at the correct vertical dimension of occlusion. This method is valuable with patients whose ridges not sacrificed during the removal of the teeth or resorbed during a long waiting period for denture construction

E. Facial measurements

Before extraction of natural teeth, the patient instructed to close the jaws into maximum occlusion, then two tattoo points have been marked, one on the upper half of the face and the other on the lower half. The distance is measured; after extraction, these measurements compared with measurements made between these points when the artificial teeth tried in.

F. Measurements from former dentures

Dentures that patient has been wearing can be measured and measurements can be correlated with observations of the patient's face to determine the amount of change required. These measurements made between the ridge crests in the maxillary and mandibular dentures with a ***Boley gauge***. Distance from the incisive papilla to the incisal edge is measured and compared to the maxillary occlusion rim. Distance from the incisive papilla to the mandibular alveolar ridge is measured and compared to the vertical distance of that of the upper and lower occlusion rims

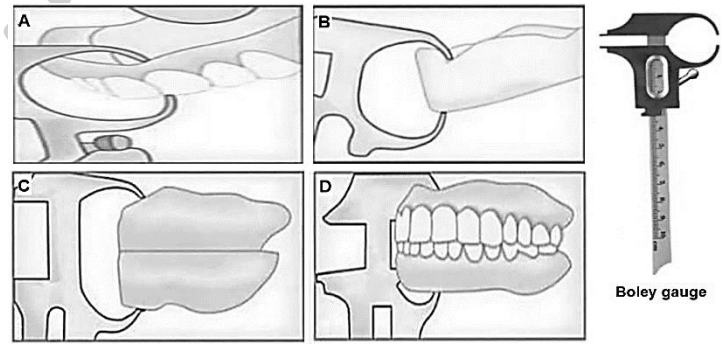

Measurements of Occlusal Vertical Dimension by Boley gauge

Dr Firas A. Farhan

2. Without Pre-extraction records:

A. Direct methods to find the occlusal vertical dimension

1. Boos method (power point):

A metal plate (*central bearing plate*) is attached to the maxillary record base. A bimeter (*an oral meter that measures pressure*) is attached to the mandibular record base. This bimeter has a dial, which shows the amount of pressure acting on it.
The record bases are inserted into the patient's mouth and the patient is asked to bite on the record bases at different degrees of jaw separation. The biting forces are transferred from the central bearing point to the bimeter. The highest value is called the power point which represents the occlusal vertical dimension.

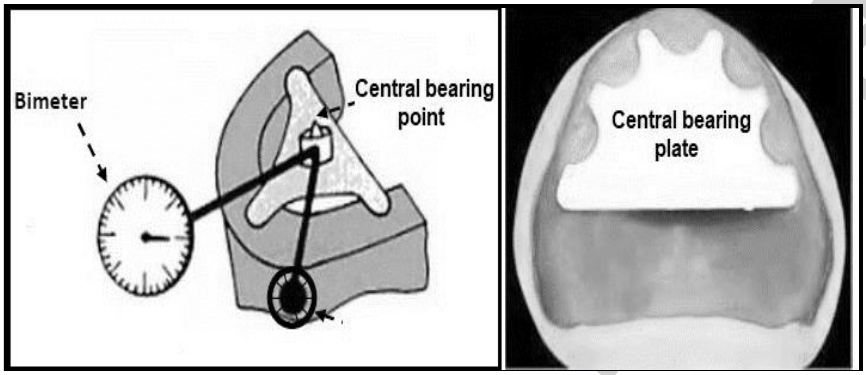

Boos method

2. Tactile sense or neuromuscular perception:

A central bearing screw/central bearing plate apparatus is used and attached to accurately adapt record bases permit the patient to experience through neuromuscular perception the different vertical relations. The central bearing screw is adjusted downward and upward until the height of contact feels right to the patient and this represents the occlusal vertical dimension.

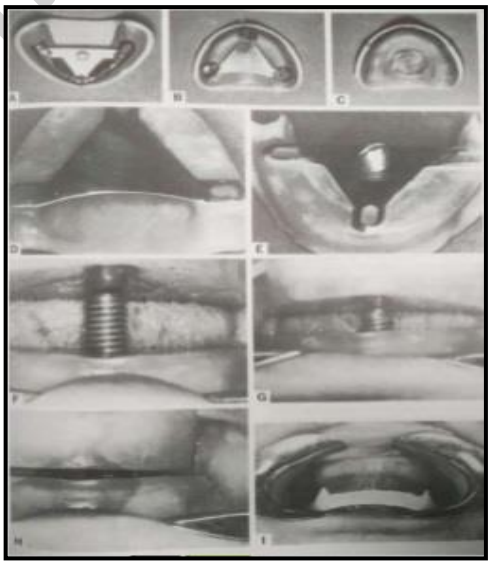

Neuromuscular perception

Dr.Firas A. Abdulameer

3. Swallowing threshold:

The technique involves fabrication of cones of soft wax on the mandibular record base. The maxillary and mandibular record bases are inserted in the patient mouth. Salivation is stimulated and the patient is asked to swallow. The repeated action of swallowing the saliva will gradually reduce the height of the wax cones to allow the mandible to reach the level of the occlusal vertical dimension.

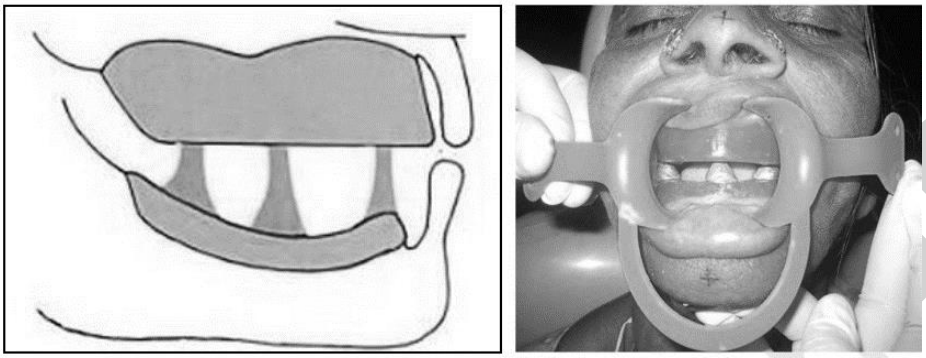

Swallowing method

4. Phonetics:

Silverman's closest speaking space*:** It is the minimal amount of inter-occlusal space between the upper and lower teeth when sounds like ***ch, ***s***, and ***j*** are pronounced. There is ***1-2 mm*** clearance between teeth when observed from the profile and frontal view.

Phonetic tests of the vertical dimension include listening to speech sound production and observing the relationships of teeth during a speech. The production of ***ch***, ***s***, and ***j*** sounds brings the anterior teeth closest together without contact.

If the distance is too large, it means that too small a vertical dimension of occlusion has been established.

If the anterior teeth contact to each other when these sounds pronounced, this indicated that the vertical dimension is probably too great.

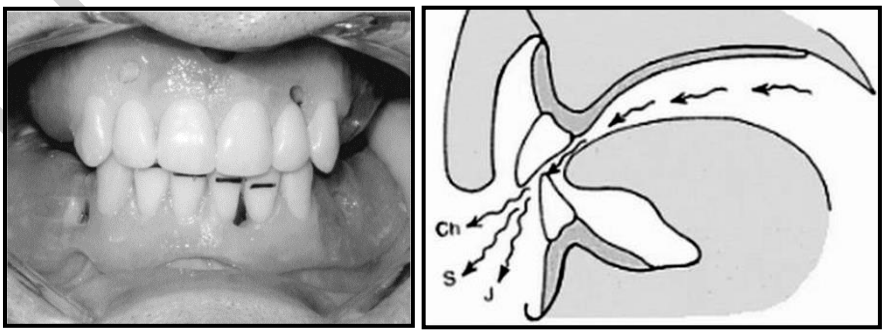

Silverman's closest speaking space

Dr Firas A. Farhan